

# Delayed Onset of Linezolid-induced Peripheral Neuropathy: A Case Report and Review with Symptom of Atypical Timeframes

SWAPNIL N DESHMUKH<sup>1</sup>, RONAK AGARWAL<sup>2</sup>, VASU AGARWAL<sup>3</sup>

CC BY-NC-ND

## ABSTRACT

Linezolid, a key drug in Multidrug-resistant Tuberculosis (MDR-TB) treatment, is known for its efficacy but is frequently associated with peripheral neuropathy, particularly with prolonged use. The authors hereby present a case of a 17-year-old young female diagnosed with extra-pulmonary MDR-TB, who developed delayed-onset peripheral neuropathy after five months of Linezolid therapy. She initially tolerated an all-oral longer regimen, including Bedaquiline, Linezolid, Cycloserine, Clofazimine, Levofloxacin and Pyridoxine. However, she later reported tingling and numbness in both lower limbs, with hyperesthesia. A neurological examination confirmed sensory axonal neuropathy. Linezolid was discontinued, leading to symptomatic improvement. To confirm, a rechallenge was performed, starting with 300 mg once daily and increasing to 600 mg once daily. Within a week, symptoms recurred, reinforcing the diagnosis of Linezolid-induced Peripheral Neuropathy (LIPN). The drug was permanently discontinued and replaced with Pyrazinamide as per Programmatic Management of Drug-resistant Tuberculosis (PMDT) guidelines. Despite its importance in MDR-TB management, there is a lack of standardised protocols for monitoring and mitigating LIPN. Future research should focus on dose-response relationships, adjunctive therapies and biochemical markers such as folate, homocysteine and oxidative stress indicators to refine treatment strategies. A balanced approach is crucial to ensuring efficacy while minimising neurotoxicity. The present case highlights the need for stringent neurological monitoring and individualised treatment adjustments in patients receiving prolonged linezolid therapy.

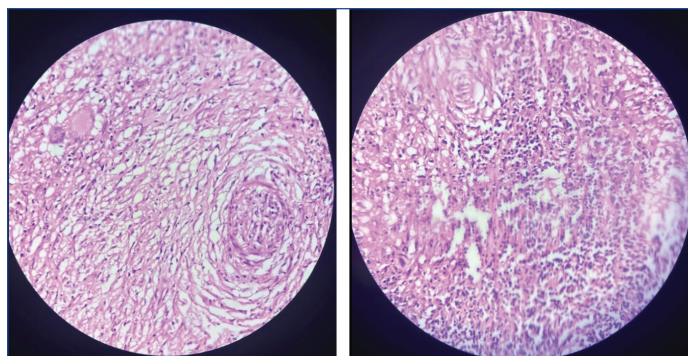
**Keywords:** Adverse drug reaction, Early neuropathy screening, Multidrug resistant, Neurotoxicity, Tuberculosis

## CASE REPORT

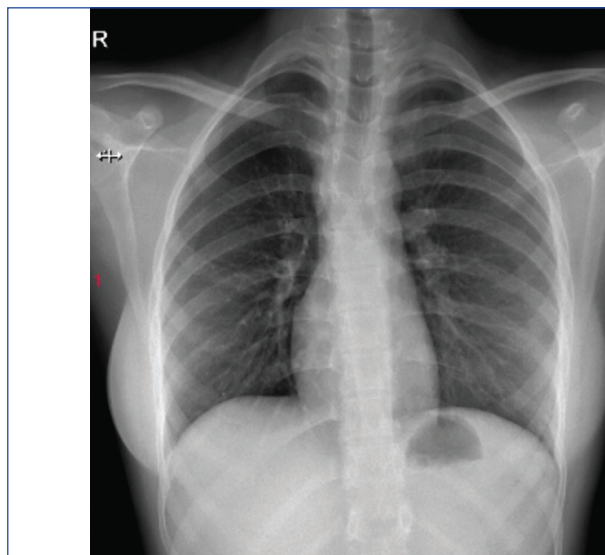
A 17-year-old young female with no significant medical history presented to the medicine Outpatient Department (OPD) with swelling associated with dull, persistent pain, localised on the left side of her neck. This swelling had been present for one month and was tender on palpation, aggravating with neck movements and relieved by Non Steroidal Anti-Inflammatory Drugs (NSAIDs) and warm compresses. She had no known co-morbidities and her general health was unremarkable. The patient was normotensive and non diabetic and serology results were negative. There were no symptoms suggestive of pulmonary involvement, such as dyspnoea, cough, or chest pain. Upon inquiry into her dietary habits, she reported consuming a mixed diet regularly. There was no past history of any neurological disorder, thyroid-related disorder, vasculitis, or any autoimmune disease.

On general physical examination, the patient was afebrile with normal vital signs. An ultrasonography of the neck revealed cervical lymphadenopathy. A tuberculin test was conducted, which returned positive. Following clinical evaluation, the decision was made to excise the neck swelling. The excised tissue was subjected to Cartridge-based Nucleic Acid Amplification Test (CBNAAT), which indicated Multi-Drug Resistant extra-pulmonary Tuberculosis (MDR-TB). Histopathological Examination (HPE) of the biopsy sample from the right cervical lymph node was suggestive of tuberculous lymphadenitis [performed using Haematoxylin & Eosin (H&E) staining] [Table/Fig-1,2]. A chest radiograph was within normal limits [Table/Fig-3]. Sputum examination for Acid-fast Bacilli (AFB) and CBNAAT was negative.

Following this diagnosis, the patient underwent a thorough pretreatment evaluation and was started on an appropriate all-oral longer regimen for tuberculosis, which included Bedaquiline (400 mg once daily for 14 days, followed by 200 mg thrice weekly), Linezolid (600 mg once daily), Cycloserine (500 mg once daily), Clofazimine (100 mg once daily), Levofloxacin (750 mg once daily)



[Table/Fig-1,2]: HPE of right cervical lymph node suggestive of tuberculous lymphadenitis (H&E, 40x). (Images from left to right)



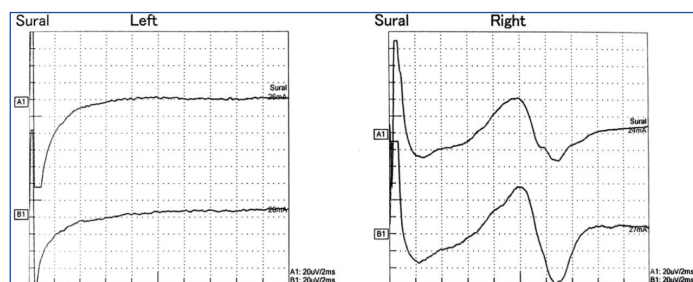
[Table/Fig-3]: Chest radiograph showing no obvious pleuro-parenchymal abnormality.

and Pyridoxine (100 mg once daily). Initially, the patient tolerated the treatment well and followed-up regularly.

However, four to five months into the treatment, she began experiencing a tingling sensation in her bilateral lower limbs, which was associated with numbness. These symptoms were progressive and accompanied by hyperaesthesia. A neurological examination of the motor system revealed normal power in all four limbs. No objective clinical evidence of peripheral or cranial nerve palsies was found; deep tendon reflexes, muscle tone and power were all normal. A detailed examination by an ophthalmologist was also normal. She reported severe, constant, burning pain with a symmetric distribution in both feet, accompanied by typical “glove and stocking” sensory impairment, with a numerical pain rating score of 10/10 (maximum).

Given the progression of her symptoms, a neurology opinion was sought. After the initial evaluation by a neurologist, Linezolid was discontinued and the patient was started on analgesics for neuropathic pain, specifically Tablet Gabapentin extended release 300 mg at bedtime and Tablet Gabapentin 100 mg twice daily.

After excluding other potential causes such as other common offending drugs, vitamin B12 deficiency and diabetes workup she was diagnosed with drug-induced peripheral neuropathy. Due to resource and financial limitations, other oxidative stress markers were not assessed, even though serum folic acid and homocysteine levels were within normal ranges. A Magnetic Resonance Imaging (MRI) scan of her spine and brain was conducted and results were within normal limits. Nerve conduction study suggested of sensory axonal neuropathy in lower limbs [Table/Fig-4]. Her family was from a lower-middle class background and none of her immediate relatives experienced these issues. Other than a regimen consisting of linezolid for treating MDR tuberculosis, she was not taking any drugs.



**[Table/Fig-4]:** Nerve conduction study showing absent Sensory Nerve Action Potential (SNAP) amplitude in both right and left sural nerves. This is suggestive of sensory axonal neuropathy.

The most likely offending drug linezolid was identified and subsequently withheld from her treatment regimen. Following this the patient's symptom improved such as, her tingling sensations in bilateral lower limbs have reduced. The identification of medication-induced toxic neuropathy was further supported by the improvement in symptoms following drug withdrawal. And then after two weeks, Linezolid was reintroduced by rechallenging dose of 300 mg once daily and fully reintroduced to 600 mg once daily, then again after a week she developed similar complaints. As reported that rechallenge was initiated at a half dose, with symptoms such as tingling (her primary complaint) monitored daily on an OPD basis before escalating to the full dose. Given the absence of established guidelines for this approach, as discussed later, further research is warranted to develop standardised strategies for managing such complications. At this point, linezolid was removed from her MDR regimen and replaced by Tablet Pyrazinamide 1250 mg O.D, as per replacement sequence of Programmatic Management of Drug-Resistant Tuberculosis (PMDT) guidelines and planned to complete treatment duration as per standard all oral longer regimen 18-24 months.

Following two months of taking analgesics and following a modified regimen, the patient's symptoms have somewhat improved,

with less tingling and numbness in both lower limbs. The patient continues to be monitored closely, with regular follow-up visits to assess her response to the adjusted treatment regimen and to ensure no further complications arises.

## DISCUSSION

The rising burden of MDR-TB has increased reliance on linezolid, a World Health Organisation (WHO) recommended drug in all-oral regimens due to its effectiveness against Mycobacterium tuberculosis. While it improves treatment success, prolonged use leads to serious neurotoxic effects, including peripheral and optic neuropathy. A growing body of literature highlights an alarming rise in neurotoxicity cases, paralleling the increased use of linezolid in MDR-TB treatment programs worldwide. As a bacteriostatic antibiotic, linezolid inhibits bacterial protein synthesis by binding to the 23S ribosomal RNA of the 50S subunit. However, its long-term use is limited by side-effects. The neurotoxicity caused by linezolid has no known cure. If a patient experiences neuropathic symptoms, they should stop taking linezolid right away. When there are no facilities to measure the serum therapeutic concentration, it is very difficult to diagnose drug-induced toxicity. Most likely, the duration of treatment has an impact on the medication's toxicity. If taken for less than 28 days, it is comparatively safe [1].

To the best of the authors knowledge, there are no established protocols for managing drug-induced neuropathies, making doctors to take a conservative approach with low-dose treatments that may inadequately relieve symptoms. This often results in under-treatment and high dropout rates. Effective measures are needed to address this growing incidence of drug-induced neuropathies, including optimising drug dosages and treatment strategies [2].

The lack of guidelines on low-dose regimens for LIPN leads to inconsistent prescribing practices. A 2017 study by Kamble SV et al., found Indian physicians preferred low-dose analgesics for neuropathic pain due to fewer side-effects. However, high-dose gabapentin and nortriptyline are more effective for LIPN. With rising Linezolid use in MDR-TB, larger studies are needed to develop standardized treatment guidelines [3].

The onset of Linezolid-induced neuropathy varies, with the present case developing symptoms after 4-5 months, while Lee S et al., (2018) reported onset at two months and Swaminathan A et al., (2017) at eight months. This suggests longer exposure increases risk. Symptom reversibility also differed, the patient improved after stopping Linezolid, but symptoms recurred on rechallenge, confirming drug toxicity. In contrast, Lee S et al., saw partial recovery, while Swaminathan A et al., reported persistent symptoms even after 21 months, highlighting the risk of irreversible damage [4,5].

Yuan Y et al., link LIPN to impaired autophagy in Schwann cells, essential for nerve repair. Linezolid exposure damages the sciatic nerve, causing myelin loss and nerve degeneration and inhibited Schwann cell proliferation, preventing recovery. The present patient's neuropathy worsened upon rechallenge, supporting Yuan Y et al., findings of progressive nerve damage and mostly irreversible nerve damage. Targeting autophagy pathways like (Protein Kinase B/ Mammalian Target of Rapamycin - AKT/mTOR signalling) may help prevent or reverse LIPN. Future research should focus on early monitoring of autophagy markers to detect neuropathy before severe damage occurs [6].

Studies like Zhang P et al., have used the Michigan Neuropathy Screening Instrument (MNSI) to assess linezolid-induced neuropathy in MDR/XDR-TB patients. Similar tools, such as the Toronto Clinical Scoring System (TCSS) and Neuropathy Disability Score (NDS), aid in screening but have limitations- MNSI relies on subjective reporting, requires trained personnel and lacks specificity for drug-induced neuropathy. Despite these challenges, their widespread implementation in TB programs could enhance early detection and intervention. Standardised neuropathy screening

protocols, including preemptive use of such tools, should be encouraged globally to prevent irreversible nerve damage in high-risk patients [7]. Juneja H et al., reported two DR-TB cases where neuropathy developed after 3-4 months of linezolid; one showed partial recovery, while the other fully recovered within three months of discontinuation [8].

Future research should develop standardised LIPN management protocols and explore dose-response relationships for optimal dosing. Investigating alternative drugs and adjunct therapies may help reduce neurotoxicity while maintaining MDR-TB treatment efficacy. Filling these gaps is crucial for better patient outcomes and improved treatment guidelines.

## CONCLUSION(S)

In conclusion, the present case highlights the need for vigilant monitoring of peripheral neuropathy in MDR-TB patients receiving linezolid. Early recognition and prompt management of drug-induced complications are crucial for patient safety and treatment success. While linezolid remains essential, its use must be carefully balanced to minimise adverse effects. Mandatory neurological evaluations before treatment can help detect pre-existing abnormalities and guide management. Standardised treatment protocols are needed to address current gaps and ensure consistent management. Given the growing support from the medical community, it is vital for health

authorities to review and update MDR-TB treatment guidelines and consider pilot programs to implement preventive measures.

## REFERENCES

- [1] Bano S, Nawaz A, Numan A, Hassan MA, Shafique MBA. A case report and literature review of the outcome of linezolid-induced optic and peripheral neuropathy in patients with multidrug-resistant pulmonary TB. *Front Neurol*. 2022;13:908584.
- [2] Deshmukh PR, Khetan H, Ranade M, Kothari K, Godbole S. Linezolid induced peripheral neuropathy- how do we treat it? *Int J Pharm Clin Res*. 2023;15(12):541-45.
- [3] Kamble SV, Motlekar SA, D'souza LL, Kudrigikar VN, Rao SE. Low doses of amitriptyline, pregabalin, and gabapentin are preferred for management of neuropathic pain in India: Is there a need for revisiting dosing recommendations? *Korean J Pain*. 2017;30(3):183-91.
- [4] Lee S, Kang BH, Ryu WY, Um SJ, Roh MS, Son C. Is severe and long-lasting linezolid-induced optic neuropathy reversible? *Intern Med*. 2018;57(24):3611-13.
- [5] Swaminathan A, du Cros P, Seddon JA, Mirgayosieva S, Asladdin R, Dusmatova Z. Peripheral neuropathy in a diabetic child treated with linezolid for multidrug-resistant tuberculosis: A case report and review of the literature. *BMC Infect Dis*. 2017;17:417.
- [6] Yuan Y, Li J, Chen Y, Cai Q, Xu Y, Lin L, et al. Mechanism underlying linezolid-induced peripheral neuropathy in multidrug-resistant tuberculosis. *Front Pharmacol*. 2022;13:946058.
- [7] Zhang P, Li W, Liu M, Zhan S, Zhang H, Deng G, et al. Linezolid-associated neuropathy in patients with MDR/XDR tuberculosis in Shenzhen, China. *Infect Drug Resist*. 2022;15:2617-24.
- [8] Juneja H, Anand KS, Garg J. Linezolid-induced peripheral neuropathy: A report of two cases. *J Int MedSci Acad*. 2024;37(1):48-49.

### PARTICULARS OF CONTRIBUTORS:

1. Senior Resident, Department of Respiratory Medicine, Dr. D. Y. Patil Medical College, Hospital and Research Centre, Dr. D. Y. Patil Vidyapeeth (Deemed to be University), Pune, Maharashtra, India.
2. Junior Resident, Department of Respiratory Medicine, Dr. D. Y. Patil Medical College, Hospital and Research Centre, Dr. D. Y. Patil Vidyapeeth (Deemed to be University), Pune, Maharashtra, India.
3. Junior Resident, Department of Respiratory Medicine, Dr. D. Y. Patil Medical College, Hospital and Research Centre, Dr. D. Y. Patil Vidyapeeth (Deemed to be University), Pune, Maharashtra, India.

### NAME, ADDRESS, E-MAIL ID OF THE CORRESPONDING AUTHOR:

Dr. Ronak Agarwal,  
Junior Resident, Department of Respiratory Medicine, Dr. D. Y. Patil Medical College, Pimpri, Pune-411018, Maharashtra, India.  
E-mail: ronakagarwal222@gmail.com

### PLAGIARISM CHECKING METHODS: [Jain H et al.]

- Plagiarism X-checker: Oct 09, 2024
- Manual Googling: Apr 05, 2025
- iThenticate Software: Apr 07, 2025 (12%)

### ETYMOLOGY: Author Origin

EMENDATIONS: 7

### AUTHOR DECLARATION:

- Financial or Other Competing Interests: None
- Was informed consent obtained from the subjects involved in the study? Yes
- For any images presented appropriate consent has been obtained from the subjects. Yes

Date of Submission: Oct 05, 2024

Date of Peer Review: Jan 30, 2025

Date of Acceptance: Apr 09, 2025

Date of Publishing: May 01, 2025